

Preclinical Evaluation of *Scorzonera* sp. Root Extracts and Major Compounds against Acute Hepatotoxicity Induced by Carbon Tetrachloride

H. ÖZBEK Ö. BAHADIR ACIKARA^{1*}, İ. KESKİN², N. İ. KIRMIZI³, T. YİĞİTBAŞI⁴, A. A. ŞAKUL AND G. SALTAN İŞCAN¹

İstanbul Medipol University, Faculty of Medicine, Department of Pharmacology, İstanbul, ¹Ankara University, Faculty of Pharmacy, Department of Pharmacognosy, Ankara, ²İstanbul Medipol University, Faculty of Medicine, Department of Histology, ³İstanbul Medipol University, Faculty of Medicine, Department of Vocational School of Health Services, ⁴İstanbul Medipol University, Faculty of Medicine, Department of Biochemistry, İstanbul, Turkey

Özbek, *et al.*: Hepatoprotection with *Scorzonera* sp.

Evaluation of hepatoprotective activities of *Scorzonera* roots and their major compounds, was aimed in current study. *Scorzonera latifolia*, *S. tomentosa*, *S. mollis* ssp. *szowitsii*, *S. parviflora* and *S. cana* var. *jacquiniana* roots, methanol-water (80:20) extracts together with chlorogenic acid, scorzotomentosin-4'-*O*- β -glucoside, hydrangenol-8-*O*- β -glucoside as major compounds isolated from *S. latifolia* roots were tested for their hepatoprotective activities. Sprague Dawley rats were used for experiment and hepatotoxicity was induced by carbon tetrachloride. Aspartate aminotransferase and alanine aminotransferase levels were measured and all results were confirmed by histopathological examination. Plasma aspartate aminotransferase and alanine aminotransferase levels of examined groups were not significant when compared to carbon tetrachloride-treated groups. However histopathological results have revealed that all tested groups have less damage when compared to carbon tetrachloride group except scorzotomentosin-4'-*O*- β -glucoside and hydrangenol-8-*O*- β -glucoside groups. *Scorzonera* species displayed moderate hepatoprotective activities against carbon tetrachloride induced acute toxicity. Chlorogenic acid, among tested compounds exhibited higher activity than all tested *Scorzonera* species as well as other isolated compounds. Therefore chlorogenic acid could be suggested as responsible compound.

Key words: *Scorzonera* sp., hepatoprotective effect, carbon tetrachloride, chlorogenic acid

In Turkish folk medicine, the roots of *Scorzonera latifolia* and similar species are mainly used as analgesic, antihelmintic, wound healer, and for treatment of women infertility^[1,2]. Additionally, the usage of this genus plants against hypertension, kidney diseases, diabetes mellitus, arteriosclerosis, and rheumatism have been recorded^[1]. Analgesic activities of the *S. latifolia*, *S. tomentosa*, *S. mollis* ssp. *szowitsii*, *S. suberosa* ssp. *suberosa* were proven scientifically by previous studies and triterpenoids were isolated as responsible compounds^[3-5]. Antiinflammatory, antioxidant, and wound healing activities have also been reported^[6-9]. Phytochemical analyses revealed that *S. latifolia* roots contained taraxasteryl myristate, taraxasteryl acetate, motiol, 3- β -hydroxy fern-8-en-7-one acetate, urs-12-en-11-one-3-acetyl, 3- β -hydroxy-fern-7-en-6-one-acetate, olean-12-en-11-one-3-acetyl, fern-7-en-3- β -one, leucodin, β -sitosterol^[3,5,10], chlorogenic acid, chlorogenic acid methyl ester,

1,5-dicaffeoyl quinic acid, 3,5-dicaffeoyl quinic acid, methylester of 3,5-dicaffeoyl quinic acid, hydrangenol-8-*O*- β -glucoside, hydrangenol-4'-*O*- β -glucoside, scorzotomentosin-4'-*O*- β -glucoside and a new isocoumarine derivative^[11] as well as scorzoveratrin 4'-*O*- β -glucoside, scorzoveratrin, scorzoveratrozit, 4,5-dicaffeoylquinic acid, 4,5-dicaffeoylquinic acid methyl ester and caffeic acid^[12]. Scorzotomentosin, scorzotomentosin-4'-*O*- β -glucoside, scorzophthalide, scorzoerzincanin, hydrangenol, hydrangenol-4'-*O*- β -glucoside, hydramacrophyllol A and B have been isolated from *S. tomentosa* roots previously^[13]. Chlorogenic acid has been determined in roots of *Scorzonera* sp.,

This is an open access article distributed under the terms of the Creative Commons Attribution-NonCommercial-ShareAlike 3.0 License, which allows others to remix, tweak, and build upon the work non-commercially, as long as the author is credited and the new creations are licensed under the identical terms

*Address for correspondence

E-mail: bahadir-ozlem@hotmail.com

Accepted 14 July 2017

Revised 04 February 2017

Received 04 November 2016

Indian J Pharm Sci 2017;79(5):715-723

including *S. latifolia*, *S. tomentosa*, *S. mollis* ssp. *szowitsii*, *S. parviflora* and *S. cana* var. *jacquiniana* as one of the major compound by high-performance liquid chromatography (HPLC)^[6,14]. Chlorogenic acid has potent antioxidant and hepatoprotective activities. Liver damage and symptoms of liver fibrosis were reduced significantly by chlorogenic acid as well as serum aspartate aminotransferase (AST) and alanine aminotransferase (ALT), alkaline phosphatase (ALP) and total bilirubin levels were lowered^[15,16]. In current study the roots of *S. latifolia*, *S. tomentosa*, *S. mollis* ssp. *szowitsii*, *S. parviflora* and *S. cana* var. *jacquiniana* were investigated for their potential hepatoprotective activities due to their high content of chlorogenic acid as well as caffeoylquinic acid derivatives. Chlorogenic acid and isocoumarine derivatives; hydrangenol-8-*O*-glucoside and scorzotomentosin-4'-*O*- β -glucoside obtained from *S. latifolia* roots as major components were also evaluated for their activities.

MATERIALS AND METHODS

Scorzonera species were collected from different parts of Turkey. The taxonomic identification of the plants was confirmed in the Department of Biological Sciences, Faculty of Art and Sciences, Gazi University. Voucher specimens are kept in the herbarium of Ankara University, Faculty of Pharmacy (Table 1). Carbon tetrachloride (CCl₄) was obtained from Merck (Darmstadt, Germany), and olive oil was obtained from Fluka (Steinheim-Germany). CCl₄ dissolved in olive oil (v/v, 1:1) and *Scorzonera* extracts were prepared using water (w/v).

Extraction of plant material:

Dried and powdered *S. latifolia* roots (700 g) were extracted with methanol-water (80:20) at room temperature for 24 h×3 times by continuous stirring. Methanol-water extract was filtered and concentrated to dryness under reduced pressure and low temperature (40-50°) on a rotary evaporator to give crude extract (182.46 g).

Isolation and identification of the compounds:

Solvent-solvent partition was performed with petroleum ether, chloroform, ethylacetate, respectively, and with the remain methanolic part four different extract were obtained. Ethylacetate part (11.02 g) was subjected to column chromatography on silica gel column eluting with ethylacetate:methanol:water (100:13.5:10) to yield 92 fraction. Fraction 24-26 and fraction 38-42 gave hydrangenol-8-*O*- β -glucoside

and scorzotomentosin-4'-*O*- β -glucoside, respectively. Chlorogenic acid was obtained from 89-92 fractions as a dirty white precipitate. Structures of the compounds were established using MS (Waters 2695 Alliance Micromass ZQ, LC/MS), ¹H and ¹³C NMR (Varian Mercury 400, 400 MHz High Performance Digital FT-NMR Spectrometer) techniques.

Experimental animals:

The study protocol (01-06-2015/41) was approved by the Ethical Committee of, İstanbul Medipol University. Male and female Sprague-Dawley rats (170-240 g) were used in this experiment. The animals were housed in standard cages (48×35×22 cm) at room temperature (22±2°), with artificial light from 7.00 am to 7.00 pm, and provided with pelleted food and water *ad libitum*.

Hepatoprotective activity assay:

Hepatotoxicity test model induced by CCl₄ was used with slight modification^[16,17]. Liver toxicity was induced by i.p. (intraperitoneal) administration of CCl₄ (0.8 ml/kg) diluted in olive oil (1:1 v/v) for two days. Animal groups were designed as follow (n=5): control group 1 received isotonic saline solution (ISS) 0.1 ml, group 2 received CCl₄ 0.8 ml/kg i.p. Group 3 received *S. cana* var. *jacquiniana* root extract (100 mg/kg)+CCl₄ (0.8 ml/kg), group 4 received *S. latifolia* root extract (100 mg/kg)+CCl₄ (0.8 ml/kg), group 5 received *S. mollis* ssp. *mollis* root extract (100 mg/kg)+ CCl₄ (0.8 ml/kg), group 6 received *S. parviflora* root extract (100 mg/kg)+CCl₄ (0.8 ml/kg), group 7 received *S. tomentosa* (100 mg/kg)+CCl₄ (0.8 ml/kg), group 8 received chlorogenic acid (5 mg/kg)+CCl₄ (0.8 ml/kg), group 9 received hydrangenol-8-*O*-glucoside (5 mg/kg)+CCl₄ (0.8 ml/kg), group 10 received scorzotomentosin-4'-*O*- β -glucoside (5 mg/kg)+CCl₄ (0.8 ml/kg) i.p. daily for seven days.

Blood samples were collected by direct cardiac puncture after seven days treatment and the serum was used for the assay of the marker enzymes AST and ALT. The percentage of daily changes in body weight was measured according to the following Eqn.: change in body weight (%) = $100 \times (\text{weight}_n - \text{weight}_{\text{initial}}) / \text{weight}_{\text{initial}}$, where, weight_{initial}: measurement on the first day, weight_n: measurement after 2., 3., ... 8th d.

Histopathological examination of the liver:

The livers of the experimental animals were fixed in 10% neutral buffered-formalin prior to routine processing in paraffin-embedded blocks. Sections

(5 µm thick) were cut and stained using Hematoxylin-eosin (HE). Axio V 16 microscope was used to take photographs. Histological damage was measured as one-blind experiment and was expressed using the following score system; 0: absent; +: mild; ++: moderate; +++: severe^[18,19]. Ballooning degeneration, sinusoidal dilatation, vascular congestion and steatosis were used for evaluation of the histopathological results.

Statistical analyses:

Results are reported as mean±SEM (standard error of mean) and as percentage (%). Kruskal-Wallis test (post hoc Mann-Whitney U with Bonferroni adjustment and Moses Extreme Reactions Test) and one-way analysis of variance (One-Way ANOVA, post hoc Scheffe) were used for statistical analyses. Probability levels of less than 0.05 (P<0.05) were considered significant.

RESULTS AND DISCUSSION

Plasma AST and ALT levels were given in Table 2. Differences in plasma AST levels of CCl₄ group and *Scorzonera* sp. extracts as well as chlorogenic acid, hydrangenol-8-*O*-β-glucoside and scorzotomentosin-4'-*O*-β-glucoside were not significant. However plasma ALT levels were measured higher than CCl₄ group after treatment of *S. mollis* ssp. *szowitsii*, *S. tomentosa* and *S. cana* var. *jacquiniana* root extracts.

Chlorogenic acid, hydrangenol-8-*O*-β-glucoside and scorzotomentosin-4'-*O*-β-glucoside groups serum ALT levels were reduced when compared to CCl₄ group.

Results of the body weight changes of animals are given in Table 3. Body weight of the animals was measured in the beginning and at the end of the study. While animals in control group (ISS) were gaining weight as measured by 2.64%, in all other groups animals had weight loss in different percentage as given in Table 3.

Histopathological examination results using score system were exhibited in Table 4. Significant differences between control (ISS) group and treatment groups were observed (P<0.05). Ballooning degeneration, sinusoidal dilatation, vascular congestion and steatosis were observed by severe score in CCl₄ treated group. Histopathological results have revealed CCl₄ treated group has high histopathological score as shown in Table 4 and remarkable results were assigned between all other treatment groups except hydrangenol-8-*O*-β-glucoside and scorzotomentosin-4'-*O*-β-glucoside treated groups (P>0.05).

In control (ISS) group no degeneration was observed in hepatocytes, sinusoids and vascular cells (fig. 1A). On the other hand CCl₄ treated group were displayed severe damage; ballooning degeneration, vascular congestion, sinusoidal dilatation and steatosis (figs. 1B and 2).

TABLE 1: VOUCHER SPECIMENS IN THE HERBARIUM

Species	Place	Herbarium number
<i>S. cana</i> (C.A. Meyer) Hoffm. var. <i>jacquiniana</i> (W. Koch) Chamberlain	Camlidere, Ankara, 2013	AEF 23834
<i>S. latifolia</i> (Fisch. & Mey.) DC.	Kop passage, 2010	AEF 23830
<i>S. mollis</i> Bieb. subsp. <i>szowitsii</i> (DC.) Chamberlain	Kizilcahamam, Ankara, 2006	AEF 23844
<i>S. parviflora</i> Jacq.	Gölbasi, Ankara, 2012	AEF 25894
<i>S. tomentosa</i> L.	Akdagmadeni, Yozgat, 2013	AEF 23841

TABLE 2: EFFECTS OF SCORZONERA SP. EXTRACTS AND COMPOUNDS ON SERUM LEVELS OF AST AND ALT

Groups	ALT	AST
	Serum (U/l)	Serum (U/l)
Control (ISS)	40.45	96.80
CCl ₄	51.15 ^a	110.25
<i>S. cana</i> var. <i>jacquiniana</i>	66.70 ^{ab}	114.10
<i>S. latifolia</i>	52.20 ^a	97.00
<i>S. mollis</i> ssp. <i>szowitsii</i>	56.30 ^{ab}	103.90
<i>S. parviflora</i>	50.60 ^a	102.00
<i>S. tomentosa</i>	62.20 ^{ab}	108.00
Chlorogenic acid	58.70	329.20
Hydrangenol-8- <i>O</i> -glucoside	39.35 ^b	111.20
Scorzotomentosin-4'- <i>O</i> -β-glucoside	33.25 ^{ab}	124.25
P value	0.034	0.457

Post-hoc Moses extreme reactions test results; ^aP<0.05 in relation to control (ISS); ^bP<0.05 in relation to CCl₄

TABLE 3: BODY WEIGHT VALUES OF THE STUDY GROUPS

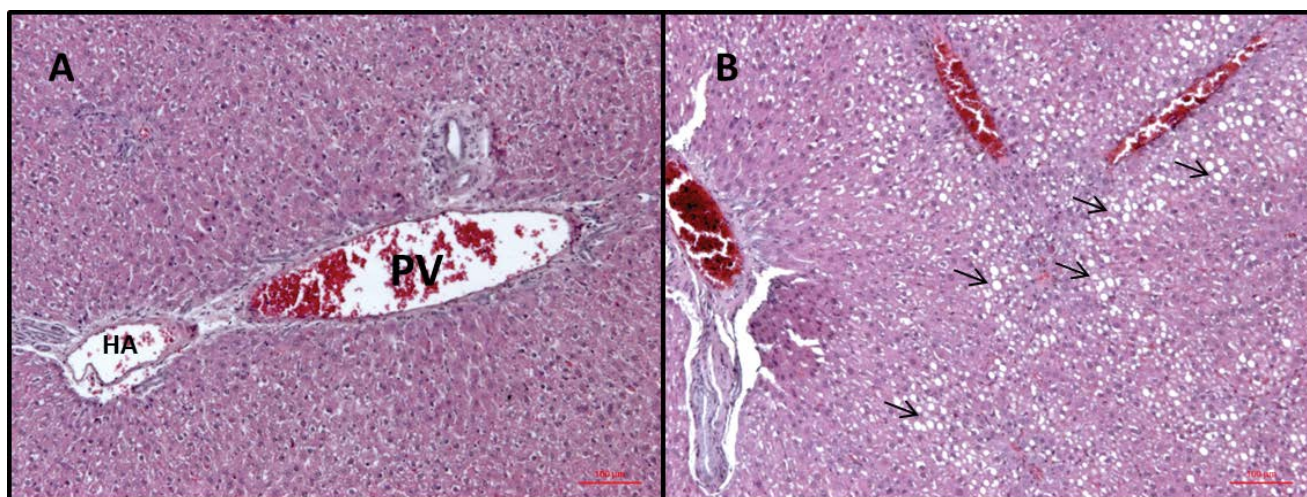
Groups	Mean	Std. deviation	Std. error	Difference (%)*
Control (ISS)	2.67	1.37	0.56	2.64
CCl ₄	-0.93	2.93	1.20	-0.95
<i>S. cana</i> var. <i>jacquiniana</i>	-6.44 ^a	4.64	2.07	-6.58
<i>S. latifolia</i>	-4.72	1.21	0.54	-4.68
<i>S. mollis</i> ssp. <i>szowitsii</i>	-3.78	3.31	1.48	-3.85
<i>S. parviflora</i>	-2.46	1.56	0.70	-2.43
<i>S. tomentosa</i>	-6.98 ^a	5.14	2.30	-6.91
Chlorogenic acid*	-11.38	-	-	-11.38
Hydrangenol-8- <i>O</i> -glucoside	-9.15 ^a	3.80	1.90	-5.91
Scorzotomentosin-4'- <i>O</i> - β -glucoside	-14.14 ^{ab}	0.98	0.70	-10.08
P value	0.001			

*Percent daily changes in body weight (%). Post-hoc Scheffe test: ^aP<0.05 comparison with control group (ISS); ^bP<0.05 comparison with CCl₄ group

TABLE 4: HISTOPATHOLOGICAL EXAMINATION RESULTS

Groups	Sinusoidal dilatation	Vascular congestion	Ballooning degeneration	Steatosis	Rate of damage	Median
Control (ISS)	0	1	0	0	1/5=0.20	0
CCl ₄	13	14	14	15	56/5=11.20	11.5 ^a
<i>S. cana</i> var. <i>jacquiniana</i>	2	5	7	1	15/3=5.00	3 ^{ab}
<i>S. latifolia</i>	3	3	12	13	31/5=6.2	3 ^{ab}
<i>S. mollis</i> ssp. <i>mollis</i>	1	5	5	4	15/5=3.00	3 ^{ab}
<i>S. parviflora</i>	3	5	5	1	14/5=2.8	3 ^{ab}
<i>S. tomentosa</i>	4	4	5	4	17/5=3.40	3 ^{ab}
Chlorogenic acid	2	2	2	2	8/5=1.60	2 ^{ab}
Hydrangenol-8- <i>O</i> -glucoside	11	11	12	13	47/5=9.40	9 ^a
Scorzotomentosin-4'- <i>O</i> - β -glucoside	12	12	14	14	52/5=10.40	11.5 ^a

^aP<0.05 comparison to control group (ISS). ^bP<0.05 comparison to CCl₄ group

**Fig. 1: Histopathological examination of liver**

Control (ISS) group (A), CCl₄ group (B). HA: hepatic artery, PV: portal vein, steatosis

Ballooning degeneration, vascular congestion, sinusoidal dilatation and steatosis were also occasionally observed in groups after treatment by hydrangenol-8-*O*- β -glucoside and scorzotomentosin-4'-*O*- β -glucoside. Steatosis areas were observed generally around central vein. Sinusoidal dilatation was also observed mainly around central vein (fig. 3).

Chlorogenic acid treatment and *S. latifolia*, *S. parviflora*; *S. mollis* ssp. *szowitsii*; *S. cana* var. *jacquiniana*; *S. tomentosa* root extracts induce recovery on cellular degeneration (figs. 4 and 5). Notable changes including less ballooning degeneration, sinusoidal dilatation, vascular congestion and steatosis were observed compared to CCl₄ treated groups. Fig. 5A displayed

S. latifolia, *S. parviflora* root extract treated groups liver. Vascular congestion and sinusoidal dilatation were detected rarely when compared as CCl_4 treated animal

livers. Nevertheless more ballooning degeneration, sinusoidal dilatation, vascular congestion and steatosis were seen compared to control (ISS) treated groups.

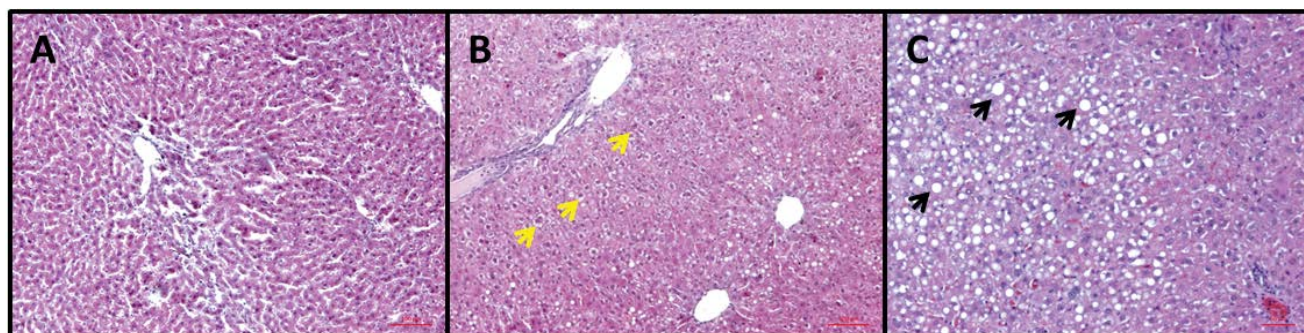


Fig. 2: Histopathological examination of liver (CCl_4 group)

A: Sinusoidal dilatation. B: ballooning degeneration. C: steatosis

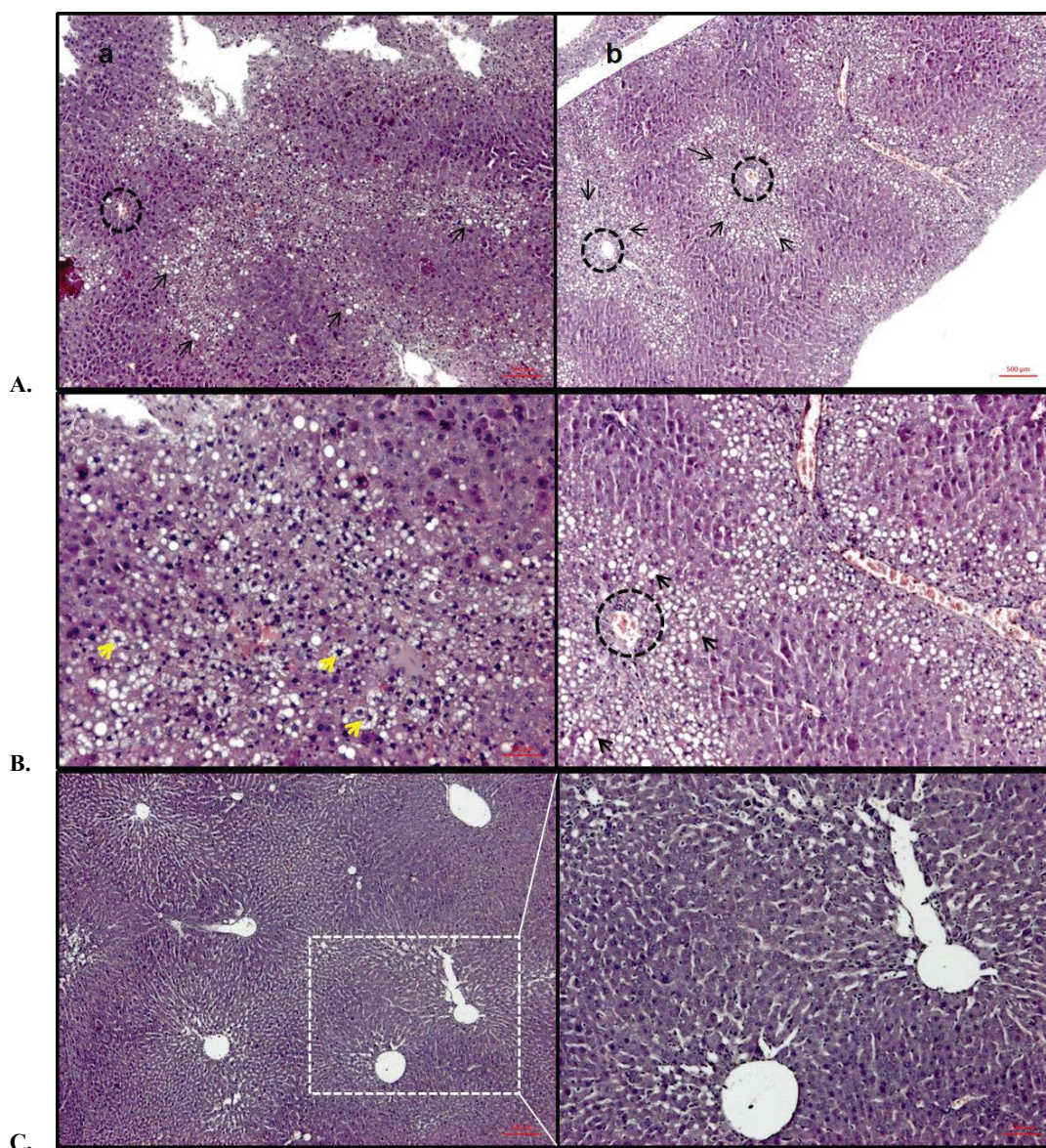


Fig. 3: Histopathological examination of liver

(A) Central vein and steatosis, (B) ballooning degeneration and steatosis, (C) sinusoidal dilatation. (a) Group scorzotomentosin-4'-O- β -glucoside and (b) group hydrangenol-8-O-glucoside

S. mollis ssp. *szowitsii* and *S. cana* var. *jacquiniana* treated groups histopathological results have revealed that ballooning degeneration was seen, however vascular congestion, sinusoidal dilatation and steatosis were scarcely as shown in figs. 5B and C. Fibrosis or fibrotic areas were also detected rarely in *S. mollis* ssp. *szowitsii* treated group animal livers (fig. 5B). Fig. 5D exhibited histopathological results of liver treated by *S. tomentosa* root extract. Ballooning degeneration, vascular congestion and sinusoidal dilatation were frequently seen. On the other hand steatosis was observed rarely (fig. 5D).

Acute liver toxicity model induced by CCl_4 was used to evaluate hepatoprotective activities of *S. latifolia*, *S. tomentosa*, *S. mollis* ssp. *szowitsii*, *S. parviflora* and *S. cana* var. *jacquiniana* root extract as well as chlorogenic acid, hydrangenol-8-*O*- β -glucoside and scorzomentosin-4'-*O*- β -glucoside obtained from *S. latifolia* roots as main components in current study.

CCl_4 -induced hepatotoxicity test model has been extensively used in animal studies to evaluate drugs can be used for treatment of liver diseases^[16,19]. CCl_4 caused to severe damages in liver such as steatosis, inflammation, apoptosis and cell necrosis^[19,20]. Giving CCl_4 to animals as a single dose mediated to necrosis and steatosis in a short time. Hepatocytes functional defects have been occurred by injuring plasma membrane, endoplasmic reticulum (ER), mitochondria and Golgi apparatus^[20,21] resulted in elevation of serum AST and ALT levels indicating hepatocellular

damage^[19]. Movement of fat from the cell is blocked by disruption of mechanism for coupling triglycerides to the appropriate apoprotein to form the lipoprotein carrier molecule is caused steatosis^[21]. The acute hepatotoxic effect of CCl_4 is due to its metabolite trichloromethyl radical ($\text{CCl}_3\cdot$) which occurred by metabolization of CCl_4 via cytochrome P-450 system. $\text{CCl}_3\cdot$ radical is converted to trichloromethyl peroxy radical $\text{CCl}_3\text{COO}\cdot$ in the presence of oxygen, is more active than the first one. These free radicals are react with different substances including proteins, nucleic acids, lipids and lead to dysfunction. Alkylation of macromolecules including cellular proteins by simultaneous attack on polyunsaturated fatty acids starts the process of lipid peroxidation leading to liver cell necrosis^[16,20]. Therefore free radical scavengers or generation inhibitors could be useful in CCl_4 -induced liver injury^[20]. CCl_4 also caused activation of many catabolic enzymes which disrupt cytoskeletal construction and cell death via apoptosis or necrosis by increasing the levels of Ca^{2+} in cells^[20].

Chlorogenic acid an ester of caffeic acid and quinic acid (3-*O*-caffeoylquinic acid (CGA)) possess significant antioxidant activity as well as antibacterial, anticarcinogenic, antiinflammatory, antihypertension activities^[22,23]. Chlorogenic acid is one of the most abundant hydroxycinnamic acid derivative in human diet and is widely distributed in medicinal plants, a number of fruits and vegetables as well as daily beverages like coffee, tea, wine, and tobacco^[22,24]. Related to its hepatoprotective activity many studies have been reported besides its other biological activities. Lipid peroxidation induced by CCl_4 has been suppressed by chlorogenic acid. 200 $\mu\text{mol/kg}$ administration of chlorogenic acid resulted in significant protection against the liver damage^[23]. According to the Shi *et al.*^[14] chlorogenic acid treatment inhibited development of hepatic fibrosis in pericentral region. Small degree of bridging fibrosis was observed. Lower severity score for liver fibrosis was determined in chlorogenic acid (60 mg/kg) treatment group when compared to CCl_4 group. It has been reported that chlorogenic acid has protective activity against liver fibrosis due to its inhibitory activity on hepatic stellate cells (HSCs) activation and production of transforming growth factor (TGF- β 1) and vascular endothelial growth factor (VEGF) as well as ER stress. Mitochondrial pathway of apoptosis in liver fibrosis could be regulated by chlorogenic acid is suggested^[14]. Serum AST, ALT and TB levels

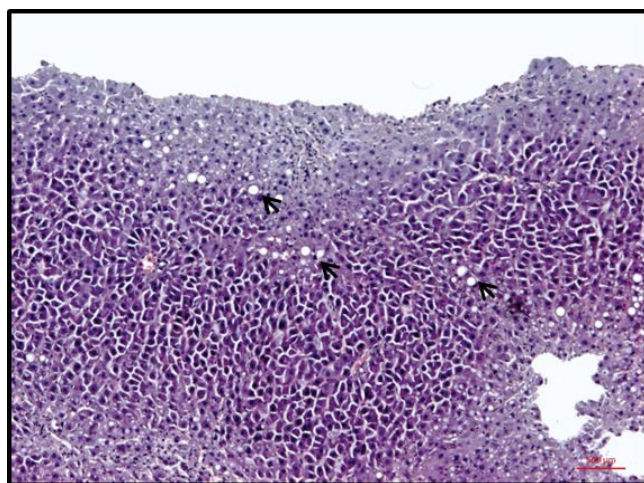


Fig. 4: Histopathological examination of chlorogenic acid-treated animal liver

Chlorogenic acid treatment induces recovery on cellular degeneration. Notable changes including less ballooning degeneration, sinusoidal dilatation, vascular congestion and steatosis were observed compared to CCl_4 -treated groups

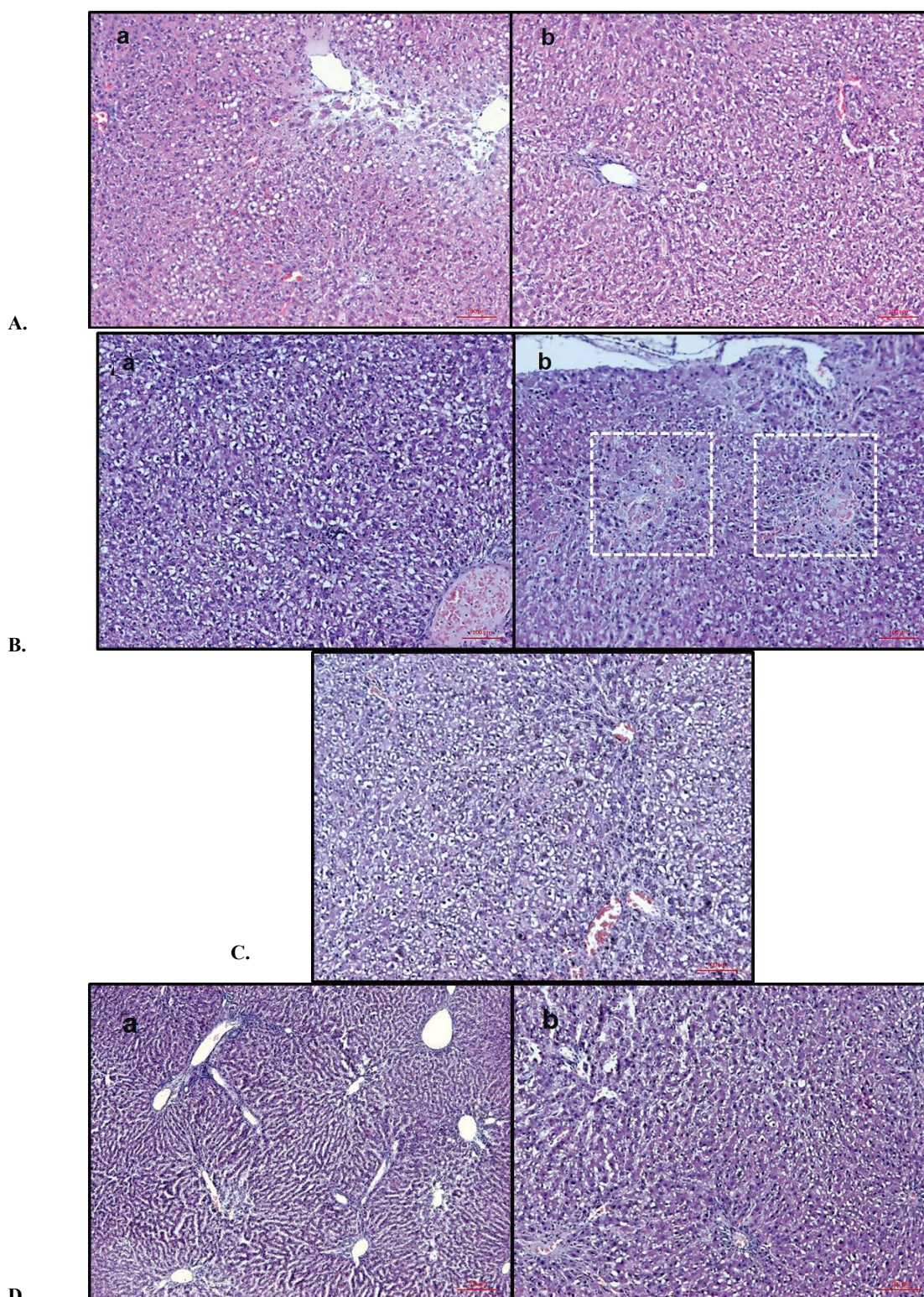


Fig. 5: Histopathological examination of liver

(A) *S. latifolia* (a) and *S. parviflora* (b) root extract-treated groups. (B) *S. mollis* ssp. *Szowitsii*-treated groups; (a) ballooning degenerations and (b) fibrotic areas. (C) *S. cana* var. *jacquiniana*-treated group. (D) *S. tomentosa* root extract-treated group; (a) vascular degeneration and sinusoidal congestion and (b) ballooning degeneration

were lowered significantly by administration of chlorogenic acid at 300 or 500 mg/kg dose while ALT levels were comparable with CCl₄ treated group.

Any mortality has not been observed up to 5000 mg/kg^[15]. Wu *et al.* reported that^[25] chlorogenic acid administration at 75 mg/kg and 150 mg/kg dose for 3 w

provided significant recovery in liver fibrosis induced by bile duct ligation. Serum alanine transaminase, AST, ALP, total bilirubin, direct bilirubin and total bile acid levels were decreased. Furthermore collagen I, collagen III, TGF- β 1 and VEGF mRNA increasing induced by BDL treatment were also suppressed by chlorogenic acid^[25]. Free radicals generated by CCl₄ metabolization via cytochrome P450 2E1 induce liver cell apoptosis and necrosis as well as upregulation of TNF- α , IL-10 and TGF- β in necrotic hepatocytes. Especially TGF- β caused progression of liver injury to chronic liver disease by activating local leucocytes and promoting the circulation of leucocytes to the necrotic area. Chlorogenic acid down regulates TGF- β 1 protein expression and decreased NF κ B expression. Furthermore pretreatment of chlorogenic acid protected the PC12 cells from β -amyloid (A β) which are reported to reduced viability of PC12 cells by reducing the level of intracellular Ca⁺² and apoptosis related of proteins. Chlorogenic acid was reported to potentiate the antiapoptotic and antifibrogenic effects of silymarin and this combination increased the expression of Bcl-2 down regulated by CCl₄^[22]. In current study chlorogenic acid was also investigated for its hepatoprotective activity in acute hepatotoxicity test model induced by CCl₄ together with hydrangenol-8-*O*- β -glucoside and scorzotomentosin-4'-*O*- β -glucoside. *Scorzonera* species were evaluated for their possible hepatoprotective activities due to their chlorogenic acid contents in present study. Biochemical results exhibited that plasma AST levels were not significant between CCl₄ group and *Scorzonera* sp. extracts as well as hydrangenol-8-*O*- β -glucoside and scorzotomentosin-4'-*O*- β -glucoside. On the other hand high levels of ALT were measured in *S. mollis* ssp. *szowitsii*, *S. tomentosa* ve *S. cana*. var. *jacquiniana* root extract treated groups while lower levels of ALT were detected in hydrangenol-8-*O*- β -glucoside and scorzotomentosin-4'-*O*- β -glucoside than CCl₄ group. Histopathological examinations clearly displayed all *Scorzonera* species tested and chlorogenic acid had less cellular damage than CCl₄ treated groups. *S. latifolia*, *S. parviflora*; *S. mollis* ssp. *szowitsii*; *S. tomentosa*, *S. cana* var. *jacquiniana* root extracts and chlorogenic acid treatment induce recovery on cellular degeneration. Chlorogenic acid treatment at 5 mg/kg dose did not lowered AST and ALT levels significantly. However histopathological examinations have revealed that recovery on cellular damage has been improved and less sinusoidal dilatation, vascular congestion, balloning

degeneration as well as steatosis were detected. All *Scorzonera* species used in current study were investigated for their chlorogenic acid contents by HPLC analyses qualitatively and quantitatively previously. *S. latifolia* roots contain higher chlorogenic acid (1246.78 \pm 3.20 μ g/g) and this was followed by *S. tomentosa* (734.72 \pm 1.04 μ g/g), *S. parviflora* (509.96 \pm 6.64 μ g/g), *S. cana* var. *jacquiniana* (331.028 \pm 2.83 μ g/g) and *S. mollis* ssp. *szowitsii* (159.25 \pm 0.24 μ g/g)^[6-7]. According to the current study *Scorzonera* root extracts displayed hepatoprotective activities probably due to their chlorogenic acid contents. Derivatives of chlorogenic acid 3,4 and 3,5 dicaffeoylquinic acids were also reported to have protective activity in CCl₄ induced hepatotoxicity^[26] which have also been isolated from some *Scorzonera* species previously^[11,12].

In conclusion, hepatoprotective activities of the tested *Scorzonera* species could be attributed to their chlorogenic acid content and its derivatives. Usage of *Scorzonera* species could be useful for hepatic diseases, furthermore chlorogenic acid is promising agent in treatment of hepatic diseases which needs further studies.

Acknowledgements:

Authors thank Prof. Hayri Duman, Plant Taxonomist, Department of Biological Sciences, Faculty of Art and Sciences, Gazi University for identifying the plant species used in this study.

Conflicts of interest:

There are no conflicts of interest.

Financial support and sponsorship:

Nil.

REFERENCES

1. Baytop T. Türkiye'de Bitkiler ile Tedavi (Therapy with Medicinal Plants in Turkey). İstanbul: Nobel Publishers; 1999.
2. Sezik E, Yesilada E, Tabata M, Honda G, Takaishi Y, Fujita T, et al. Traditional medicine in Turkey VIII. Folk medicine in East Anatolia; Erzurum, Erzincan, Ağrı, Kars, Iğdir Provinces. Econ Bot 1997;51:195-211.
3. Bahadır Ö, Saltan Çitoğlu G, Smejkal K, Dall'Acqua S, Özbek H, Cvacka J, et al. Analgesic compounds from *Scorzonera latifolia* (Fisch. and Mey.) DC. J Ethnopharmacol 2010;131:83-7.
4. Bahadır Ö, Saltan HG, Özbek H. Antinociceptive activity of some *Scorzonera* L. Species. Turk J Med Sci 2012;42:861-6.
5. Bahadır Acıkara Ö, Saltan Çitoğlu G, Dall'Acqua S, Özbek H,

- Cvacka J, Zemlicka M, *et al.* Bioassay-guided isolation of the antinociceptive compounds motiol and beta-sitosterol from *Scorzonera latifolia* root extract. *Pharmazie* 2014;69:711-4.
6. Küpeli Akkol E, Bahadır Acıkara Ö, Süntar İ, Saltan Çitoğlu G, Keleş H, Ergene B. Enhancement of wound healing by topical application of *Scorzonera* species: Determination of the constituents by HPLC with new validated reverse phase method. *J Ethnopharmacol* 2011;137:1018-27.
 7. Süntar İ, Bahadır Acıkara Ö, Saltan Çitoğlu G, Keleş H, Ergene B, Küpeli Akkol E. *In vivo* and *in vitro* evaluation of the therapeutic potential of some Turkish *Scorzonera* species as wound healing agent. *Curr Pharm Design* 2012;18:1421-33.
 8. Küpeli Akkol E, Bahadır Acıkara Ö, Süntar İ, Ergene B, Saltan Çitoğlu G. Ethnopharmacological evaluation of some *Scorzonera* species: *In vivo* antiinflammatory and antinociceptive effects. *J Ethnopharm* 2012;140:261-70.
 9. Bahadır Acıkara Ö, Süntar İ, Saltan Çitoğlu G, Keleş H, Ergene B, Akkol Küpeli E. Determination of phenolic acids and flavonoids and antiinflammatory activity of *Scorzonera* species. *Int J Pharmacog Phytochem Res* 2014;6:59-65.
 10. Bahadır Acıkara Ö, Saltan Çitoğlu G, Dall'Acqua S, Smejkal K, Cvacka J, Zemlicka M. A new triterpene from *Scorzonera latifolia* (Fisch. & Mey.) DC. *Nat Prod Res* 2012;26:1892-7.
 11. Bahadır Acıkara Ö, Hosek J, Babula P, Cvacka J, Budesinsky M, Dracinsky M, *et al.* Turkish *Scorzonera* Species Extracts Attenuate Cytokine Secretion via NF- κ B Inhibition Showing Promising Anti-inflammatory Effect. *Molecules* 2016;21:1-14.
 12. Sarı A. Phenolic compounds from *Scorzonera latifolia* (Fisch. & Mey.) DC. *Nat Prod Res* 2012;26:50-5.
 13. Sarı A, Zidorn C, Spitaler R, Ellmerer EP, Ozgokce F, Orgama KH, *et al.* Phenolic compounds from *Scorzonera tomentosa* L. *Helv Chim Acta* 2007;90:311-31.
 14. Shi H, Dong L, Bai Y, Zhao J, Zhang Y, Zhang L. Chlorogenic acid against carbontetrachloride-induced liver fibrosis in rats. *Eur J Pharm* 2009;623:119-24.
 15. Sun Z, Liu S, Zhao Z, Su R. Protective Effect of Chlorogenic Acid against Carbon Tetrachloride-induced Acute Liver Damage in Rats. *Chinese Herbal Medicine* 2014;6:36-41.
 16. Citoğlu GS, Bahadır Acıkara Ö, Sever Yılmaz B, Ozbek H. Evaluation of analgesic, antiinflammatory and hepatoprotective effects of lycorine from *Sternbergia fisheriana* (Herbert) Rupr. *Fitoterapia* 2012;83:81-7.
 17. Mistry S, Dutt KR, Jena J. Protective effect of *Sida cordata* leaf extract against CCl₄ induced acute liver toxicity in rats. *Asian Pac J Trop Med* 2013;6:280-4.
 18. Abdel-Wahhab MA, Nada SA, Arbid MS. Ochratoxicosis: prevention of developmental toxicity by L- methionine in rats. *J Appl Toxicol* 1999;19:7-12.
 19. Zhang Z, Liu Y, Lu L, Luo P. Hepatoprotective activity of *Gentiana veitchiorum* Hemsl. Against carbon tetrachloride-induced hepatotoxicity in mice. *Chin J Nat Med* 2014;12:488-94.
 20. Toori MA, Joodi B, Sadeghi H, Sadeghi H, Jafari M, Talebianpoor MS, *et al.* Hepatoprotective activity of aerial parts of *Otostegia persica* against carbon tetrachloride-induced liver damage in rats. *Avicenna J Phytomed* 2015;5:238-46.
 21. Tiwari P, Ahirwae D, Chandy A, Ahirwar B. Evaluation of hepatoprotective activity of alcoholic and aqueous extracts of *Selaginella lepidophylla*. *Asian Pas J Trop Dis* 2014;4:81-6.
 22. Al-Rasheed NM, Fadda LM, Al-Rasheed NM, Ali HM, Yacoub HI. Down-Regulation of NF κ B, Bax, TGF- β , Smad-2mRNA expression in the Livers of Carbon Tetrachloride Treated Rats using Different Natural Antioxidants. *Braz Arch Biol Technol* 2016;59:1-10.
 23. Zhou J, Ashoori F, Suzuki S, Nishigaki I, Yagi K. Protective Effect of Chlorogenic Acid on Lipid Peroxidation Induced in the Liver of Rats by Carbon Tetrachloride or Co-Irradiation. *J Clin Biochem Nutr* 1993;15:119-25.
 24. El-Seedi HR, El-Said AMA, Khalifa SAM, Göransson U, Bohlin L, Borg-Karlson AK, *et al.* Biosynthesis, natural sources, dietary intake, pharmacokinetic properties and biological activities of hydroxyl cinnamic acids. *J Agric Food Chem* 2012;60:10877-95.
 25. Wu D, Bao C, Li L, Fu M, Wang D, Xie J, *et al.* Chlorogenic acid protects against cholestatic liver injury in rats. *J Pharm Sci* 2015;129:177-82.
 26. Basnet P, Matsushige K, Hase K, Kadota S, Namba T. Four di-O-caffeoyl quinic acid derivatives from propolis potent hepatoprotective activity in experimental liver injury models. *Biol Pharm Bull* 1996;19:1479-84.